

# Severe COVID-19 Treatment Using Hypoxic-Mesenchymal Stem Cell Secretome: A Case Report

Siufui Hendrawan<sup>1,2,\*</sup>, Sandy Qlintang<sup>3</sup>, Ronald Winardi Kartika<sup>4</sup>, Vera Kurniawati<sup>5</sup>, David Victorious Lukas<sup>6</sup>

<sup>1</sup> Department of Biochemical and Molecular Biology, Faculty of Medicine, Tarumanagara University, Jakarta

<sup>2</sup> Tarumanagara Human Cell Technology Laboratory, Jakarta

<sup>3</sup> Stem Cell and Cancer Institute Kalbe, Jakarta

<sup>4</sup> Faculty of Medicine, Krida Wacana Christian University, Jakarta

<sup>5</sup> Faculty of Medicine, Pelita Harapan University, Tangerang

<sup>6</sup> Director of Marketing, P.T. Ananta Karya Sejahtera, Tangerang

\*Corresponding author. Email: [siufui@fk.untar.ac.id](mailto:siufui@fk.untar.ac.id)

## ABSTRACT

COVID-19 (SARS COV-2) has a serious adverse effect in the form of Acute Respiratory Distress Syndrome (ARDS) caused by a hyper-inflammation event ('cytokine storm') that causes damage to the lung tissue. Previous studies have shown a link between disease severity and excessive elevation of pro-inflammatory cytokines, such as tumor necrosis factor-alpha (TNF- $\alpha$ ) and interleukin 6 (IL-6). This discovery is substantiated by the plasma cytokine levels found in the majority of patients suffering from severe COVID-19 with extensive lung damage.

Recently, mesenchymal stem cells (MSCs) have shown their potency in combating the cytokine storm due to their immune-modulatory, anti-inflammation, and paracrine effects. MSCs cultured under hypoxic conditions may increase the activity of solutes known as Secretome-MSCs (S-MSCs), such as interleukin 10 (IL-10), and transforming growth factor beta (TGF- $\beta$ ), which are considered as principal contributing factors in reducing inflammation. In addition, they can also increase the expression of growth factors such as vascular endothelial growth factor (VEGF) and fibroblast growth factor (FGF) that accelerate the repair of the lung injury.

In this case report, we report an effective therapy to control the COVID-19 cytokine storm that regenerates damaged lungs. A severely ill COVID-19 patient with comorbidities suffered ARDS. Standard therapy was given with no improvement. Secretome-MSCs administration was suggested. A total of 7 vials were injected in the patient via an intramuscular route. Two weeks after the last dose was administered, the patient's condition significantly improved. Current clinical findings show the curative prospect of secretome-MSC in the therapy of COVID-19 related ARDS.

**Keywords:** Covid-19, Cytokine storm, Secretome-Mesenchymal Stem Cell.

## 1. BACKGROUND

The current novel coronavirus disease (COVID-19), which initially occurred in Wuhan, China at the end of 2019, had rapidly spread to more than 200 countries worldwide. This pandemic has caused an unprecedented challenge to public health and is devastating the economic and social spheres. This pandemic is perpetrated by the severe acute respiratory syndrome coronavirus 2 (SARS-CoV-2), infecting almost 200 million people with mortality rates of around 2%

globally [1], [2]. This virus is transmitted from human to human through respiratory droplets, aerosols, or contaminated surfaces [3]–[6].

Clinical manifestations of this disease vary from asymptomatic or mild to severe symptoms such as cough, fever, or shortness of breath, to respiratory failure and multiple organ dysfunction [5], [7]. SARS-CoV-2 uses the angiotensin-converting enzyme II (ACE2) receptor as cell entry receptor and type 2 transmembrane serine 2 protease (TMPRSS2) for S

protein priming [5], [8]. The SARS-CoV-2 attacks the lungs because both of these proteins are found on alveolar type II cells and capillary endothelial cells of the lungs [5], [6], [9]. The pathogenesis related to the lung damage is the effect of the virus either directly destroying these cells or indirectly diminishing the immune response [10]. Once the infection has been established by the virus, it is identified by the innate immune system that leads to the expression of type I interferon (IFN) which has antiviral activity [11]. This immune response is important for the successful eradication of the virus. However, the virus can evade the immune response, moreover, triggering an overreaction of the defence mechanisms which causes an inflammatory hyper-response that becomes more harmful than the initial aggression and known as 'cytokine storm'. Cytokine storm is responsible for acute respiratory distress syndrome (ARDS), other lung abnormalities like pneumonitis, and causing 'ground glass' opacity in the lungs [12]. The progression of this condition could evolve swiftly and culminates in a high mortality rate, which is approximately around 40% due to ARDS-caused cytokine storms [6]. At the end of 2020, data from a COVID-19 referral hospital in Jakarta, Indonesia revealed that the intensive care unit (ICU) occupancy had escalated to 80%. Furthermore, in one of the most referred COVID-19 hospitals, patients with COVID-19 related pneumonia in the ICU had a mortality rate as high as 87% [13]. In this case report, we report an effective therapy to control the COVID-19 cytokine storm that regenerates damaged lungs. The patient had given the consent to use his medical record data for this case report.

## 2. CASE PRESENTATION

A 35-year-old male patient suspected of COVID-19 was admitted to the private hospital on April 28, 2021. This patient also had medical history of hypertension and diabetes as comorbidities. On admission, he presented with a fever, cough, shortness of breath, nausea, and emesis. His vital signs were abnormal (Table 1). Furthermore, he was diagnosed with dyspnoea, bilateral pneumonia, ARDS, and coagulopathy. After the real time-reverse transcription polymerase chain reaction (RT PCR) test he was confirmed with COVID-19. The blood oxygen saturation of the patient was very low (SpO<sub>2</sub>: 68%). He was given High Flow Nasal Cannula (HFNC) (FiO<sub>2</sub>: 80%) with a flow rate of 60 liters per minute (lpm) to assist ventilation, and the SpO<sub>2</sub> rose to 97%. He showed the abnormal level of C-reactive protein (CRP) (218.92 mg/L) and IL-6 was 3.06 pg/mL. The clinical laboratory features of the patient are shown in table 2. The X-Ray imaging showed ill-defined bilateral airspace consolidation with predominance peripheral distribution

(Figure 1). He was treated with routine antivirals for COVID-19, and other supportive treatments for the symptoms (Table 3).

In the evening the condition of these severely ill patients was not improved, suggesting that the current therapy was not effective. The therapy of secretome-MSC was proposed. The secretome-MSC was produced by PT. Bifarma Adiluhung (Certificate on Good Manufacturing Practice: GMP/CPOB/A/X/19). The secretome-MSC was derived from human umbilical cord and cultured in hypoxic condition. He was injected with 1 vial (1.5 mL) of secretome-MSCs via intramuscular.

On April 29, he was injected again with 1 vial of secretome-MSC in the morning, followed by a second dose of secretome-MSC in the evening. He was still on the HFNC and the breathing pattern was still not effective (Table 2). The X-Ray imaging showed radiological worsening (ground glass opacity). Extensive progressive bilateral airspace consolidation is more pronounced on the right lung (Figure 1).

On April 30, he still showed dyspnoea, hypoxia, and ARDS. The HFNC was still maintaining to assist his breathing. D-dimer result was higher than normal level (12.62 µg/mL). The secretome-MSCs treatments were given in the same doses as the day before. He showed higher levels of pH, bicarbonate, and white blood cells.

On May 1, the shortness of breath had reduced. He was given another 1 vial of secretome-MSCs via intramuscular injection.

On May 2, another 1 vial of secretome-MSCs was injected into the patient. The dyspnoea was reduced but the breathing pattern was still ineffective.

On May 3, the HFNC was changed into non-rebreather mask (NRM). He was recovered from shortness of breath (Table 1).

On May 5, the breathing pattern was normal, the NRM treatment was removed, D-dimer level was decreased to 5 µg/mL and the CRP gradually decreased from 218.92 mg/L before treatment and returned to the normal level of 4 mg/L. The IL-6 level was 5 pg/mL, which was higher compared to the result from April 28 and 30. The X-Ray imaging showed improvement compared to the previous results, although it still showed bronchopneumonia.

On May 6, he was discharged from the hospital and continue with outpatient care.

On May 17, based on the X-Ray imaging of the chest, the result was remarkably improved after administration of 7 vials of secretomes. The current appearance of the lung is nearly normal (Figure 1).

**Table 1.** Vital sign of patient during in hospital

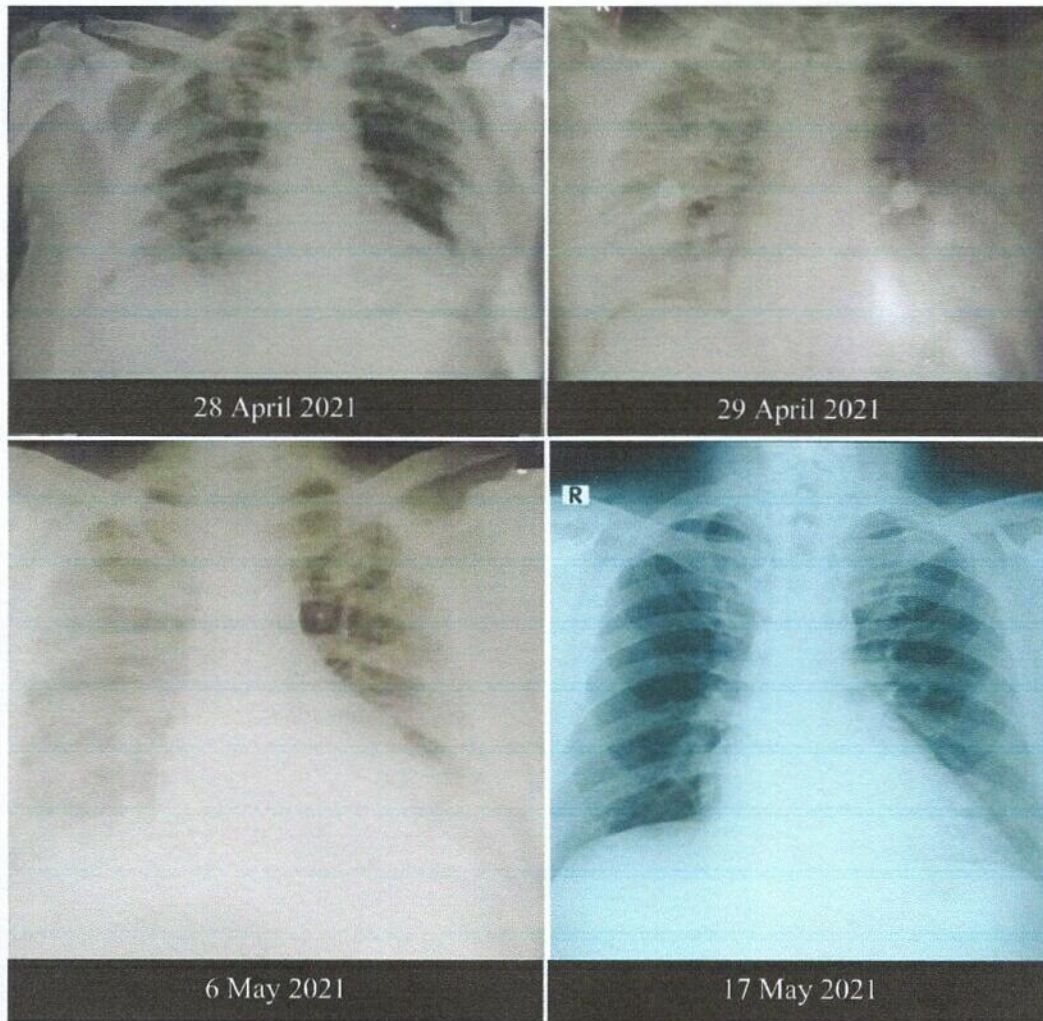
Variable	28-Apr	29-Apr	30-Apr	1-May	2-May	3-May	4-May	5-May
BP	165/110	150/110	150/90	160/110	135/90	138/95	130/80	120/80
RR	30	25	27	24	24	25	24	22
HR	110	105	100	88	71	88	84	80
SpO <sub>2</sub>	80	97	98	98	96	98	98	98
HFNC	FiO <sub>2</sub> 80%, 60 lpm	FiO <sub>2</sub> 80%, 50 lpm	FiO <sub>2</sub> 80%, 50 lpm	FiO <sub>2</sub> 80%, 50 lpm	FiO <sub>2</sub> 70%, 40 lpm			
NRM						15 lpm	10 lpm	

**Table 2.** The clinical laboratory characteristics of this severely ill COVID-19 patient

Date	Normal Range	28-Apr	29-Apr	30-Apr	1-May	2-May	3-May	4-May	5-May	Unit
RBC	4.6-6.2	5.84		5.5						10e6/ $\mu$ L
WBC	5-10	6.4	-	11.29	-	-	-	-	-	10e3/ $\mu$ L
Hb	13-18	16.4	-	15.3	-	-	-	-	-	g/dL
Ht	40-54	-	-	46.3	-	-	-	-	-	%
Platelet	150-440	204	-	272	-	-	-	-	-	10e3/ $\mu$ L
NEU	50-70	-	-	79.1	-	-	-	-	-	%
LYM	18-48	-	-	10.5	-	-	-	-	-	%
ALT	0-41	70.5	-	-	-	-	-	-	-	U/L
AST	0-38	48.4	-	-	-	-	-	-	-	U/L
Ureum	18-55	48.4	-	48.9	-	-	-	-	-	mg/dL
Creatinine	< 1.17	0.79	-	0.79	-	-	-	-	-	mg/dL
CRP	< 5	218.92	-	-	-	-	-	4	4	mg/L
PCT	< 0.046	0.1	-	-	-	-	-	-	-	ng/mL
D-dimer	< 0.5	-	-	12.62	-	-	3.59	5.17	5	$\mu$ g/mL
IL-6	$\leq$ 7.0	3.06	-	3	-	-	-	-	5	pg/mL

**Table 3.** Treatments of the patient during in hospital (Blue colour indicates treatment were given)

Treatments	28-Apr	29-Apr	30-Apr	1-May	2-May	3-May	4-May	5-May
Antiviral (Favipiravir 200 mg)	2 x 1600 mg	2 x 1600 mg	2 x 1600 mg	2 x 1600 mg	2 x 1600 mg	2 x 1600 mg	2 x 1600 mg	2 x 1600 mg
Antibiotics (Azithromycin 500 mg, Cephalosporine)	AZT 1 x 500 mg, Ceph 2 x 1	AZT 1 x 500 mg, Ceph 2 x 1	AZT 1 x 500 mg, Ceph 2 x 1	AZT 1 x 500 mg, Ceph 2 x 1	AZT 1 x 500 mg, Ceph 2 x 1	AZT 1 x 500 mg, Ceph 2 x 1	AZT 1 x 500 mg, Ceph 2 x 1	AZT 1 x 500 mg, Ceph 2 x 1
Anti-inflammation (Dexamethasone)	2x1	2x1	2x1	2x1	2x1	2x1	2x1	2x1
Heparin	3 x 1000 iu	3 x 5000 iu s.c	3 x 5000 iu s.c	3 x 5000 iu s.c	3 x 5000 iu s.c			
UC-MSc Secretome 1.5 ml	1x1	2x1	2x1	1x1	1x1			
Standard COVID-19 drugs plus anti-diabetic and anti-hypertension								



**Figure 1** The X-Ray images of this severely ill COVID-19 patient

### 3. DISCUSSION

Cytokine storm can occur as a result of the invasion of hyper-inflammatory immune cells (neutrophils and macrophages) at the pulmonary site hyper-activation of T-helper 1 (Th1) cells, along with upregulation of pro-inflammatory cytokines such as interleukin 6 (IL-6), tumor necrosis factor-alpha (TNF- $\alpha$ ), interleukin 1 (IL-1), interferon-gamma (IFN- $\gamma$ ), IFN-induced protein 10 (IP10), monocyte chemoattractant protein-1 (MCP-1), inflammatory macrophage protein-1a (MIP-1a), and granulocyte-colony stimulating factor (G-CSF) [5], [6].

There are still no definite drugs to cure COVID-19. Neither are there specific vaccines available to prevent this infection [14]. Currently, the treatment plan of COVID-19 is only supportive which entails the administration of antiviral and antibiotic agents, while severe cases require additional invasive ventilation. Several trials of repurposing antivirals, drugs, neutralizing antibodies, and convalescent plasma as treatment of COVID-19 were done but the effectiveness

of these treatments is still in question. In this case report, the patient was given the standard therapy for COVID-19 such as antiviral and antibiotic with additional HFNC due to the severity of the condition, which showed no improvement after the standard therapy.

Therefore, to combat this unusual virulence, new therapeutic strategies must be explored. Mesenchymal Stem Cells (MSCs) have appeared as an innovative and potential choice for severe COVID-19 patients due to their abilities to repair tissue and suppress overactive immune responses. It has been proven in many studies that the focal role of MSCs for providing therapeutic potential lies in their paracrine activity. MSCs produce a complex mixture of soluble protein including extracellular vesicles (EVs), cytokines, and growth factors during in vitro culture, especially cultured under hypoxic condition [6]. Hypoxia was identified as a better condition to enhance growth factors such as VEGF, keratinocyte growth factor (KGF), hepatocyte growth factor (HGF), and FGF [15]. This intricate

compound is called a secretome or a conditioned medium, which showed immunomodulatory, anti-inflammatory, and regenerative capabilities [6]. Cell-free therapies for COVID-19 such as the usage of secretome-MSCs have been studied in ARDS-COVID-19 related cases [16], [17]. This cell-free therapies were commonly given via intravenous (IV) [16], [18]. When given intravenously, the secretome-MSCs remained highly stable in the blood flow then distributed through the lungs [19], [20].

However, in this case report, the secretome-MSCs, was administered intramuscularly. The IM route was chosen in this case to give the sustained release and prolonged the effect from the soluble factors that contained in the secretome-MSCs. Other studies also performed intramuscular (IM) administration for MSC treatment and showed that IM route is particularly beneficial for the secreted biomolecules and minimally invasive compared to the conventional IV infusion route [21].

A total of 7 vials of secretome-MSCs were injected to the patient intramuscularly. The condition of the patient was gradually improved. Two weeks after the last dose of secretome-MSC was administered, the patient's lung was significantly improved compared to the condition on the day he was admitted to the hospital (Figure 1).

This remarkable improvement is due to the role of the secretome-MSC that contains many anti-inflammatory cytokines such as IL-10, TGF- $\beta$ , interleukin 1 receptor antagonist (IL1ra), TNF $\alpha$ -stimulated gene-6 (TSG6), which are thought to be key determinants in reducing inflammation, inhibit cytokine storm, and opposing the symptoms that are associated with COVID-19. Moreover, this secretome-mediated immune suppression and establishment of an anti-inflammatory environment can significantly quash the viral infection. This mechanism will directly restore the lung microenvironment and as a result, the overall clinical outcome will improve [22].

#### 4. CONCLUSION

Current clinical findings show the curative prospect of secretome-MSC in the therapy of COVID-19 related ARDS. Further clinical trials are needed to evaluate the doses, route of transmissions, and timing of secretome-MSCs administration. The development of standard operating procedures (SOPs) for obtaining Good Manufacturing Practice (GMP)-grade secretome-MSC are necessary for further clinical applications.

#### AUTHORS' CONTRIBUTIONS

Siufui, Sandy, and Ronald contributed to write the article; Sandy helped to provide the secretome-MSC,

Vera provided the medical record data. David helped in the editing and reviewing process.

#### ACKNOWLEDGMENTS

The private hospital for allowing and providing the medical record data. Inge Friska Widjaya as radiologist consultant.

#### REFERENCES

- [1] WHO, "WHO Coronavirus (COVID-19) Dashboard," 2021. <https://covid19.who.int/> (accessed Aug. 12, 2021).
- [2] D. Baud, X. Qi, K. Nielsen-Saines, D. Musso, L. Pomar, and G. Favre, "Real estimates of mortality following COVID-19 infection," *Lancet Infect. Dis.*, vol. 20, no. 7, p. 773, 2020, doi: 10.1016/S1473-3099(20)30195-X.
- [3] Y. Chen, Q. Liu, and D. Guo, "Emerging coronaviruses: Genome structure, replication, and pathogenesis," *J. Med. Virol.*, vol. 92, no. 4, pp. 418–423, 2020, doi: 10.1002/jmv.25681.
- [4] N. Zhu *et al.*, "A Novel Coronavirus from Patients with Pneumonia in China, 2019," *N. Engl. J. Med.*, vol. 382, no. 8, pp. 727–733, 2020, doi: 10.1056/nejmoa2001017.
- [5] N. Eiro, J. R. Cabrera, M. Fraile, L. Costa, and F. J. Vizoso, "The Coronavirus Pandemic (SARS-CoV-2): New Problems Demand New Solutions, the Alternative of Mesenchymal (Stem) Stromal Cells," *Front. Cell Dev. Biol.*, vol. 8, no. July, pp. 1–11, 2020, doi: 10.3389/fcell.2020.00645.
- [6] A. Chow, T. Milanda, C. R. Sartika, M. N. Kirana, D. Halim, and A. Faried, "Potency of Mesenchymal Stem Cell and Its Secretome in Treating COVID-19," *Regen. Eng. Transl. Med.*, 2021, doi: 10.1007/s40883-021-00202-5.
- [7] Z. Wu and J. M. McGoogan, "Characteristics of and Important Lessons from the Coronavirus Disease 2019 (COVID-19) Outbreak in China: Summary of a Report of 72314 Cases from the Chinese Center for Disease Control and Prevention," *JAMA - J. Am. Med. Assoc.*, vol. 323, no. 13, pp. 1239–1242, 2020, doi: 10.1001/jama.2020.2648.
- [8] P. Zhou *et al.*, "A pneumonia outbreak associated with a new coronavirus of probable bat origin," *Nature*, vol. 579, no. 7798, pp. 270–273, 2020, doi: 10.1038/s41586-020-2012-7.
- [9] M. Hoffmann *et al.*, "SARS-CoV-2 Cell Entry Depends on ACE2 and TMPRSS2 and Is Blocked by a Clinically Proven Protease Inhibitor," *Cell*,

- vol. 181, no. 2, pp. 271-280.e8, 2020, doi: 10.1016/j.cell.2020.02.052.
- [10] Y. Jin *et al.*, "Virology, Epidemiology, Pathogenesis, and Control of COVID-19," *Viruses*, vol. 12, no. 4, p. 372, Mar. 2020, doi: 10.3390/v12040372.
- [11] E. Prompetchara, C. Ketloy, and T. Palaga, "Immune responses in COVID-19 and potential vaccines: Lessons learned from SARS and MERS epidemic," *Asian Pacific J. Allergy Immunol.*, vol. 38, no. 1, pp. 1-9, 2020, doi: 10.12932/AP-200220-0772.
- [12] Y. Shi *et al.*, "COVID-19 infection: the perspectives on immune responses," *Cell Death Differ.*, vol. 27, no. 5, pp. 1451-1454, 2020, doi: 10.1038/s41418-020-0530-3.
- [13] I. H. Dilogo *et al.*, "Umbilical cord mesenchymal stromal cells as critical COVID-19 adjuvant therapy: A randomized controlled trial," *Stem Cells Transl. Med.*, vol. 10, no. 9, pp. 1279-1287, 2021, doi: 10.1002/sctm.21-0046.
- [14] C. R. Harrell, B. P. Jovicic, V. Djonov, and V. Volarevic, "Therapeutic Potential of Mesenchymal Stem Cells and Their Secretome in the Treatment of SARS-CoV-2-Induced Acute Respiratory Distress Syndrome," *Anal. Cell. Pathol.*, vol. 2020, no. Figure 1, 2020, doi: 10.1155/2020/1939768.
- [15] S. Hendrawan *et al.*, "Wound healing potential of human umbilical cord mesenchymal stem cell conditioned medium: An in vitro and in vivo study in diabetes-induced rats," *Vet. World*, vol. 14, pp. 2109-2117, Aug. 2021, doi: 10.14202/vetworld.2021.2109-2117.
- [16] T. Maron-Gutierrez and P. R. M. Rocco, "Cell-Free Therapies: Novel Approaches for COVID-19," *Front. Immunol.*, vol. 11, no. September, pp. 2-7, 2020, doi: 10.3389/fimmu.2020.583017.
- [17] R. Y. Mahida, S. Matsumoto, and M. A. Matthay, "Extracellular vesicles: A new frontier for research in acute respiratory distress syndrome," *Am. J. Respir. Cell Mol. Biol.*, vol. 63, no. 1, pp. 15-24, 2020, doi: 10.1165/rcmb.2019-0447TR.
- [18] T. G. Shah, D. Predescu, and S. Predescu, "Mesenchymal stem cells-derived extracellular vesicles in acute respiratory distress syndrome: a review of current literature and potential future treatment options," *Clin. Transl. Med.*, vol. 8, no. 1, pp. 4-9, 2019, doi: 10.1186/s40169-019-0242-9.
- [19] E. Bari, I. Ferrarotti, L. Saracino, S. Perteghella, M. L. Torre, and A. G. Corsico, "Mesenchymal Stromal Cell Secretome for Severe COVID-19 Infections: Premises for the Therapeutic Use," *Cells*, vol. 9, no. 4, pp. 5-9, 2020, doi: 10.3390/cells9040924.
- [20] M. Morishita, Y. Takahashi, M. Nishikawa, and Y. Takakura, "Pharmacokinetics of Exosomes—An Important Factor for Elucidating the Biological Roles of Exosomes and for the Development of Exosome-Based Therapeutics," *J. Pharm. Sci.*, vol. 106, no. 9, pp. 2265-2269, 2017, doi: 10.1016/j.xphs.2017.02.030.
- [21] L. R. Braid, C. A. Wood, D. M. Wiese, and B. N. Ford, "Intramuscular administration potentiates extended dwell time of mesenchymal stromal cells compared to other routes," *Cytotherapy*, vol. 20, no. 2, pp. 232-244, 2018, doi: 10.1016/j.jcyt.2017.09.013.
- [22] A. Mahajan and S. Bhattacharyya, "A brief review on potential application of mesenchymal stem cell and secretome in combating mortality and morbidity in COVID-19 patients," *Biomed. J.*, vol. 44, no. 1, pp. 63-73, 2021, doi: 10.1016/j.bj.2020.09.003.

Part of **SPRINGER NATURE**

[PROCEEDINGS](#) | [JOURNALS](#) | [BOOKS](#)

---

Search

Series: [Advances in Health Sciences Research](#)

## Proceedings of the 1st Tarumanagara International Conference on Medicine and Health (TICMIH 2021)

---

PREFACE

---

The 1st Tarumanagara International Conference on Medicine and Health (TICMIH) 2021 was held by Consortium of Health Science of LLDIKTI Region III collaborated with Untar Institute of Research & Community Engagement (LPPM Untar). It was held online from August 5 to 6, 2021, using Zoom Platform.

The conference brought a topic about "Challenges and Opportunities for Overcoming Infectious Diseases in the 21st Century." The keynote speakers at this conference were Professor Tania Sorrell, MD., Ph.D., from the University of Sydney, Australia (subtopic: Global trends in emerging infectious diseases – How to manage them) and Dr. dr. Erni J. Nelwan, Sp.PD., Ph.D., from the University of Indonesia (subtopic: Emerging infectious diseases in Indonesia: Where are we now?).

This conference facilitated lecturers, students, and researchers to publish their articles in indexed international proceeding. The scope of the articles included but was not limited to the following: Medicine, Health, Public Health, Infectious Disease & Tropical Medicine, Community Medicine, Dentistry, Pharmacy, Nursing, Nutrition, Obstetrics, and Clinical Psychology.

Articles submitted to TICMIH 2021 was reviewed by expert reviewers before being presented. The results of those reviewed articles were later be further reviewed to be published according to the scientific publication standard

criteria and requirements.

TICMIH 2021 Organizing Committee would like to thank Prof. Dr. Agus Setyo Budi, M.Sc, as the Head of Administration of LLDIKTI Region III at Ministry of Education and Culture of the Republic of Indonesia; Prof. Dr. Agustinus Purna Irawan as the Rector of Tarumanagara University; Ir. Jap Tji Beng, Ph.D. as the Head of LPPM Untar; Dr. dr. Saelan Tadjudin, Sp.KJ as the Dean of Untar Medical Faculty; Dr. dr. Meilani Kumala, MS., Sp.GK(K); Chairperson, members, and PIC of Consortium of Health Science of LLDIKTI Region III; TICMIH 2021 Organizing Committee; the Authors included in this proceeding; and all parties who contributed to this conference.

Jakarta, November, 2021  
Organizing Committee  
Dr. dr. Arlends Chris, M.Si.

## Atlantis Press

Atlantis Press – now part of Springer Nature – is a professional publisher of scientific, technical & medical (STM) proceedings, journals and books. We offer world-class services, fast turnaround times and personalised communication. The proceedings and journals on our platform are Open Access and generate millions of downloads every month.

For more information, please contact us at: [contact@atlantis-press.com](mailto:contact@atlantis-press.com)

- ▶ PROCEEDINGS
- ▶ JOURNALS
- ▶ BOOKS
- ▶ POLICIES
- ▶ MANAGE COOKIES/DO NOT SELL MY INFO
- ▶ ABOUT
- ▶ NEWS
- ▶ CONTACT
- ▶ SEARCH



Copyright © 2022 Atlantis Press -    Springer Nature

Part of **SPRINGER NATURE**

[PROCEEDINGS](#) | [JOURNALS](#) | [BOOKS](#)

Search

Series: [Advances in Health Sciences Research](#)

## Proceedings of the 1st Tarumanagara International Conference on Medicine and Health (TICMIH 2021)

PROCEEDINGS OF THE 1ST TARUMANAGARA INTERNATIONAL CONFERENCE ON MEDICINE AND HEALTH (TICMIH 2021)

<

>

### Severe COVID-19 Treatment Using Hypoxic-Mesenchymal Stem Cell Secretome: A Case Report

#### Authors

Siufui Hendrawan<sup>1, 2, \*</sup>, Sandy Qlintang<sup>3</sup>, Ronald Winardi Kartika<sup>4</sup>, Vera Kurniawati<sup>5</sup>, David Victorious Lukas<sup>6</sup>

<sup>1</sup> Department of Biochemical and Molecular Biology, Faculty of Medicine, Tarumanagara University, Jakarta

<sup>2</sup> Tarumanagara Human Cell Technology Laboratory, Jakarta

<sup>3</sup> Stem Cell and Cancer Institute Kalbe, Jakarta

<sup>4</sup> Faculty of Medicine, Krida Wacana Christian University, Jakarta

<sup>5</sup> Faculty of Medicine, Pelita Harapan University, Tangerang

<sup>6</sup> Director of Marketing, P.T. Ananta Karya Sejahtera, Tangerang

\* Corresponding author. Email: [siufui@fk.untar.ac.id](mailto:siufui@fk.untar.ac.id)

#### Corresponding Author

Siufui Hendrawan

Available Online 1 December 2021.

#### DOI

<https://doi.org/10.2991/ahsr.k.211130.049> [How to use a DOI?](#)

#### Keywords

<https://www.atlantis-press.com/proceedings/ticmih-21/125965109>

## Covid-19; Cytokine storm; Secretome-Mesenchymal Stem Cell

### Abstract

COVID-19 (SARS COV-2) has a serious adverse effect in the form of Acute Respiratory Distress Syndrome (ARDS) caused by a hyper-inflammation event ('cytokine storm') that causes damage to the lung tissue. Previous studies have shown a link between disease severity and excessive elevation of pro-inflammatory cytokines, such as tumor necrosis factor-alpha (TNF- $\alpha$ ) and interleukin 6 (IL-6). This discovery is substantiated by the plasma cytokine levels found in the majority of patients suffering from severe COVID-19 with extensive lung damage.

Recently, mesenchymal stem cells (MSCs) have shown their potency in combating the cytokine storm due to their immune-modulatory, anti-inflammation, and paracrine effects. MSCs cultured under hypoxic conditions may increase the activity of solutes known as Secretome-MSCs (S-MSCs), such as interleukin 10 (IL-10), and transforming growth factor beta (TGF- $\beta$ ), which are considered as principal contributing factors in reducing inflammation. In addition, they can also increase the expression of growth factors such as vascular endothelial growth factor (VEGF) and fibroblast growth factor (FGF) that accelerate the repair of the lung injury.

In this case report, we report an effective therapy to control the COVID-19 cytokine storm that regenerates damaged lungs. A severely ill COVID-19 patient with comorbidities suffered ARDS. Standard therapy was given with no improvement. Secretome-MSCs administration was suggested. A total of 7 vials were injected in the patient via an intramuscular route. Two weeks after the last dose was administered, the patient's condition significantly improved.

Current clinical findings show the curative prospect of secretome-MSC in the therapy of COVID-19 related ARDS.

### Copyright

© 2021 The Authors. Published by Atlantis Press International B.V.

### Open Access

This is an open access article under the CC BY-NC license.

[+ Download article \(PDF\)](#)



**Volume Title**

Proceedings of the 1st Tarumanagara International Conference on Medicine and Health (TICMIH 2021)

**Series**

Advances in Health Sciences Research

**Publication Date**

1 December 2021

**ISBN**

978-94-6239-473-5

**ISSN**

2468-5739

**DOI**

<https://doi.org/10.2991/ahsr.k.211130.049> [How to use a DOI?](#)

**Copyright**

© 2021 The Authors. Published by Atlantis Press International B.V.

**Open Access**

This is an open access article under the CC BY-NC license.

**Cite this article**

---

ris

enw

---

bib

---

TY - CONF  
AU - Siufui Hendrawan  
AU - Sandy Qlintang

AU - Ronald Winardi Kartika  
AU - Vera Kurniawati  
AU - David Victorious Lukas  
PY - 2021  
DA - 2021/12/01  
TI - Severe COVID-19 Treatment Using Hypoxic-Mesenchymal Stem Cell Secretome: A Case Report  
BT - Proceedings of the 1st Tarumanagara International Conference on Medicine and Health (TICMIH 2021)  
PB - Atlantis Press  
SP - 290  
EP - 295  
SN - 2468-5739  
UR - <https://doi.org/10.2991/ahsr.k.211130.049>  
DO - <https://doi.org/10.2991/ahsr.k.211130.049>  
ID - Hendrawan2021  
ER -




[+ download .ris](#) [COPY TO CLIPBOARD](#)

## Atlantis Press

Atlantis Press – now part of Springer Nature – is a professional publisher of scientific, technical & medical (STM) proceedings, journals and books. We offer world-class services, fast turnaround times and personalised communication. The proceedings and journals on our platform are Open Access and generate millions of downloads every month.

For more information, please contact us at: [contact@atlantis-press.com](mailto:contact@atlantis-press.com)

- ▶ PROCEEDINGS
- ▶ JOURNALS
- ▶ BOOKS
- ▶ POLICIES
- ▶ MANAGE COOKIES/DO NOT SELL MY INFO
- ▶ ABOUT
- ▶ NEWS
- ▶ CONTACT
- ▶ SEARCH

[Home](#) [Privacy Policy](#) [Terms of use](#)     
Copyright © 2006-2022 Atlantis Press – now part of Springer Nature